

# Determination of fetal head station during labor - An innovative method combining ultrasound and spatial positioning

Paltieli Y<sup>1</sup>, Lewinsky RM<sup>2</sup>, Gonen R<sup>1</sup>, Ohel G<sup>1</sup>

<sup>1</sup> Bnai Zion Medical Center, Israel; <sup>2</sup> Trig Medical Ltd., Israel

## Introduction

Intra-partum assessment of the fetal head station is essential for the correct and safe management of labor. Routine trans-vaginal digital examinations (TVDE) are characterized by significant inconsistency in assessing fetal head station. We present a new device – the LaborPro (Trig Medical, Neshar, Israel), employing a PC and magnetic position sensors for easy determination of fetal head station and position during labor (Figure 1).

## Methods

Using the position sensors, the maternal pelvis is mapped and the spatial position of the pelvic inlet is determined. An ultrasound abdominal transducer is calibrated with the positioning system. Fetal head station is determined by either marking the fetal BPD plane or the lowermost part of the fetal skull (“Tip”) in relation to the pelvic inlet. This study presents the results of 70 BPD and 159 Tip examinations performed on 44 women in labor. All measurements were taken contiguous to TVDE which was used as control. Comparison between groups was performed by paired t-test.

## Results

The mean ( $\pm$ STD) differences between TVDE and BPD or Tip station determinations, were  $0.8 \pm 0.8$  cm ( $P=0.76$ ) and  $1.1 \pm 1$  cm ( $P=0.55$ ), respectively. Comparison between LaborPro BPD and tip measurements in 42 cases showed difference of  $0.4 \pm 0.3$  cm ( $P=0.46$ ).

## Discussion

It is common knowledge that the clinical assessment of fetal head station is characterized by a significant inter-observer variability. This study reports the initial experience with the non-invasive LaborPro device, which employs the textbook standard of relating the fetal BPD plane to the pelvic inlet plane and, therefore, provides for the first time a tool for the accurate and consistent assessment of fetal head station by ultrasound during active labor.

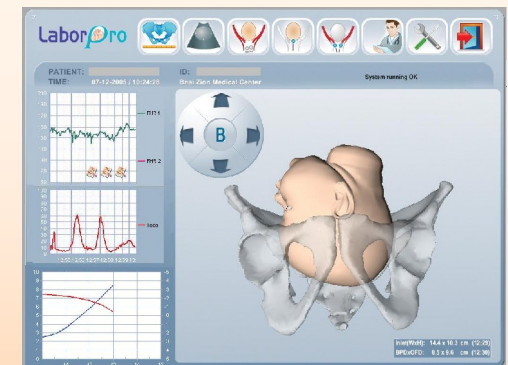
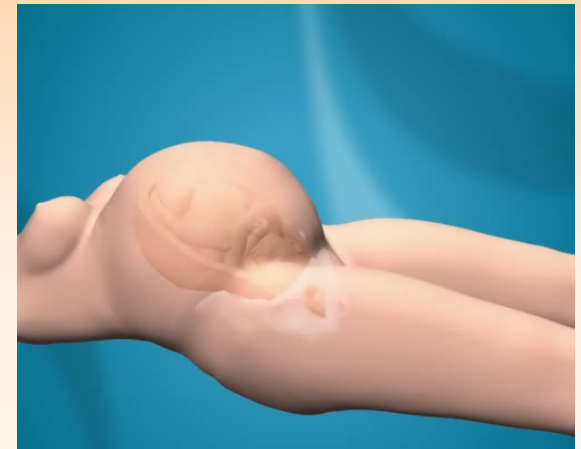

Figure 1 : LaborPro display of fetal skull station and position